

Cellular and humoral local immune responses in sheep experimentally infected with *Oestrus ovis* (Diptera: Oestridae)

Guillaume TABOURET, Caroline LACROUX, Olivier ANDREOLETTI,
Jean Paul BERGEAUD, Yacob HAILU-TOLOSA, Hervé HOSTE,
Françoise PREVOT, Christelle GRISEZ, Philippe DORCHIES,
Philippe JACQUIET*

UMR 959 INRA/DGER de Physiopathologie Infectieuse et Parasitaire des Ruminants,
École Nationale Vétérinaire, 23 chemin des Capelles, 31076 Toulouse, France

(Received 28 May 2002; accepted 12 November 2002)

Abstract – Cellular and humoral local responses were investigated following repetitive artificial *Oestrus ovis* infections in lambs. The presence of larvae induced a huge local recruitment of either leucocytes (T and B lymphocytes, macrophages) or granulocytes (eosinophils, mast cells and globule leucocytes). This cellular response was more pronounced in the ethmoid and sinus (development sites of second and third instar larvae) than in the septum or turbinates where first instar larvae migrate. Infected lambs produced *Oestrus ovis* specific IgG and IgA antibodies in their mucus. This local humoral response was mainly directed against larval salivary gland antigens and not against larval digestive tract antigens. Compared to the control animals, the sinusal mucosa of infected animals was extremely thickened and the epithelium exhibited hyperplasia, metaplasia and eosinophilic exocytosis. The possible roles of these local immune responses in the regulation of *O. ovis* larvae populations in sheep are discussed.

Oestrus ovis / local immune response / lymphocyte / eosinophil / IgA and IgG immunoglobulins

1. INTRODUCTION

Grazing sheep are exposed to a wide variety of parasites such as gastrointestinal nematodes, liver flukes, cestodes and myiasis agents. Oestrosis, caused by *Oestrus ovis* (Linné 1758) larvae, is a common myiasis of sheep affecting nasal and sinusal cavities. Female flies deposit first instar larvae on the sheep nostrils. These

larvae actively penetrate into the nasal cavities. L1 larvae migrate from the nasal septum and turbinates to the ethmoid where the first moult to L2 larvae occurs. L2 larvae migrate towards the sinus where they moult to L3 larvae. During the early phase of L3 growth, an intense weight gain occurs [3]. L3 larvae are then expelled by the host sneezings onto the ground where they pupate [23]. Parasitic larval stages

* Correspondence and reprints
Tel.: (33) 5 61 19 39 67; fax: (33) 5 61 19 39 44; e-mail: p.jacquet@envt.fr

might be considered as mesoparasites since they evolve in open cavities and do not need any intra-tissular passage. Infection in sheep, and to a lesser extent goats, induces a bilateral nasal discharge consecutive to mucus hypersecretion. Necropsic observations in naturally infected sheep showed a strong inflammation of the mucosae [4] which for a long time was thought to be a consequence of mechanical trauma induced by larval spines and hooks. However, since histochemical studies of septal, turbinate and ethmoid mucosae have demonstrated that eosinophils and mast cells are more numerous in the chorion of naturally or experimentally infected sheep and goats [14, 15], the inflammatory process could result from the activation of these cellular subsets. The experimental infection of lambs with first instar larvae induces a systemic IgG response detected by ELISA fifteen days after the L1 larvae were deposited [5]. Nevertheless, many elements of the local immune response remain uncharacterised, especially the recruitment of mononuclear cells and the local production of immunoglobulins in infected mucosae. The role of such a local response in the regulation of *O. ovis* populations remains unknown, although epidemiological studies showed lower parasitic burdens in ewes than lambs (Dorchies, unpublished data) suggesting the progressive development of specific immunity with flystrike exposure. Moreover, establishment rates of *O. ovis* larvae after experimental infections are higher in immunosuppressed than in control or immunostimulated animals [11] suggesting that larval populations could be affected by the local immune response.

The aims of this study were (i) to investigate the recruitment of lymphocytes and macrophages to the mucosa of infected animals by immunohistochemistry, (ii) to confirm the recruitment of granulocytes, especially, eosinophils, mast cells and globule leucocytes and to extend the field of investigation to the sinus mucosa which

has never been studied. Furthermore, since mature larvae are found in the sinus cavities and since we suspected that they were mostly responsible for lesions, an anatomo-pathological study of sinus mucosae was done, (iii) to assess the presence of local IgG and IgA responses against various larval antigens by ELISA.

2. MATERIALS AND METHODS

2.1. Infective *O. ovis* larvae recovery and preparation

Oestrus ovis first instar larvae (L1) were collected from naturally infected sheep. L1 were washed in sterile PBS (pH 7.2) six times and resuspended in a physiological saline solution (pH 7). The viability of the larvae was determined under a dissecting microscope.

2.2. Preparation of *O. ovis* larvae excretory secretory products (ES)

Second (L2) and third (L3) instar larvae were collected from naturally infected sheep heads. These larvae were washed six times in PBS with Penicillin-Streptomycin 5% (500 UI/mL and 500 µg/mL) and incubated in sterile PBS (500 µL/larvae) containing Penicillin-Streptomycin 1% for 24 h at room temperature in the dark. Then, the supernatants were collected, centrifuged (10 000 × g) and filtered through 0.8/0.2 µm sieves. Protein concentration was determined by the bicinchoninic acid assay method (Pierce, Rockford, Illinois, USA) and the ES solution was stored at -70 °C until use.

2.3. Preparation of digestive tract and salivary gland contents

The larvae of late second and third stages were dissected in ice cold PBS. The whole digestive tracts (DT) and the

salivary gland rings (SG) were collected and centrifuged at $10\,000 \times g$ to expel their contents (DTc and SGc). The protein concentration of the supernatants was determined as above and these were stored frozen ($-70\text{ }^{\circ}\text{C}$) until use.

2.4. Animals and experimental design

Eleven 4 month old *O. ovis* free “Tarasconnais” lambs were randomly allocated into two groups: 6 lambs in the infected group and 5 in the control group. The animals were housed indoors on concrete floors with straw bedding; the feed was given *ad libitum*. Three separate infections were made one week apart. Two batches of 30 L1 (right and left nostrils) were administered during the first infection, 2×15 L1 during the second one and 2×10 L1 during the third and last one, so that each animal received a total of 110 L1. Larvae were deposited in the nostril with a plastic pipette with a flexible tip. Necropsies were done nine weeks after the first infection. After splitting the heads, larvae were collected from the septal, turbinate and ethmoid surfaces as well as the sinus cavities, were counted and their stages (L1, L2 and L3) were identified. Immediately after death, two tissue samples (1 cm^2) were taken from each of the septal, turbinate, ethmoid and sinus surfaces and fixed either in 10% buffered formaldehyde or Carnoy for histological studies (see below).

2.5. Mucus sampling

Mucus samples were collected by absorption onto filter paper strips of 4 cm^2 each. PBS impregnated strips were deposited on the septal mucosa for five minutes on each side. The strips were then gently agitated in PBS for two hours at room temperature. The supernatants were centrifuged and stored frozen at $-70\text{ }^{\circ}\text{C}$ until ELISA analysis.

2.6. Immunohistochemistry (IHC) and histochemistry (HC)

Immunohistochemistry: tissue sections (2 microns thick) were laid onto adhesive treated slides (ChemMate Capillary Gap Microscope Slides, S 2024, DAKO, Trappes, France) and dried overnight at $56\text{ }^{\circ}\text{C}$ before being deparaffinised and rehydrated. A haematoxylin-eosin stained section was used as a quality control. For IHC, tissue sections were autoclaved for 20 min at $121\text{ }^{\circ}\text{C}$ in 10 mM citrate buffer (pH 6.10) and cooled for 20 min. Endogenous peroxidase was inhibited using a 1:100 dilution of hydrogen peroxide 30% (w/w) in methyl alcohol for 30 min at room temperature. Washing steps were performed with tap-water. Tissue sections were then incubated with 20% normal goat serum in tris saline buffer for 20 min to block non-specific binding sites. Anti-CD antibodies were either mAbs specific for human CD68 (clone Ki-M6 monocyte/macrophage, Serotec, 1:150 dilution), human CD20-like (clone BLA36, B lymphocytes, Novocastrea, Le Perray en Yvelines, France, 1:50 dilution), or a rabbit anti-human CD3 antibody (A 0452, T lymphocytes, DAKO, 1:100 dilution). An anti Ki67 monoclonal antibody (R521-7, DAKO) was diluted to 1:50. Incubation with a primary antibody (60 min) was followed by 30 min incubation with HRP labelled secondary antibody (1:100 diluted), specific for either rabbit or mouse immunoglobulin heavy chains. Revelation was performed using diaminobenzamide (DAB). Each step was followed by washes with 1% skimmed milk-0.05% Tween 20 in TBS. Sections were counterstained with Mayer haematoxylin. All steps were carried out at room temperature. Infected and control group samples were assessed by counting T lymphocytes (peri-vascular, chorionic and intra-epithelial) chorionic B lymphocytes and macrophages. Each sample of mucosa was analysed by counting 5 different optical fields at high magnification ($\times 400$).

Table I. Modifications and alterations of the sinus mucosa in infected and control animals.

Tissue	Alteration	Infected sheep (N = 6)	Control sheep (N = 5)
Epithelium	Hyperplasia	2.67	0.25
	Metaplasia	1.33	0
	Goblet cells	0	3.67
	Cilia reduction	4	0
	Eosinophilic exocytosis	2.33	0
Lamina propria	Multifocal irregularities	1.33	0
Chorion	Oedema	3	0.5

1 = minimum, 2 = light, 3 = moderate, 4 = marked, 5 = severe.
The results are expressed as the means of the infected and control sheep.

Histochemistry: in the nasal and sinus mucosae, eosinophils and globule leucocytes were counted after carbol chromotrope staining. An alcian blue safranin stain was used to count the mast cells. Immunoglobulin-containing cells were easily identified by the presence of the archoplasm (Golgi apparatus). Cellular counts were done as described above. After hemalun eosin staining, sections of turbinate, septal, ethmoid and sinus mucosae were examined and the lesions were semi-quantitatively described. The criteria mentioned in Table I were graded from 1 to 5 as follows: 1 = minimum, 2 = light, 3 = moderate, 4 = marked, 5 = severe.

2.7. Enzyme-linked immunosorbent assay (ELISA)

An indirect ELISA was used. Briefly, each well of a flat-bottomed microtitre plate (Nunclon Distr. VWR International, Strasbourg, France) was coated with 100 µL of ES, DTc or SGc at 5 µg/mL in sodium carbonate buffer pH 9.6 for 2 h at 37 °C. The plates were washed three times in PBS pH 7.2 containing 0.05% Tween 20 (PBS-T). To minimise non-specific binding of the antibody, the plates were then incubated for 2 h at room temperature with 200 µL of PBS-T with 4% skimmed milk powder (PBS-TSM). Subsequently the plates were washed three times with

PBS-T before adding 100 µL of mucus preparation (diluted 1:25 in PBS) to each well for 1 h at 37 °C. After three washes with PBS-T, 100 µL of horseradish peroxidase labelled anti-ovine IgG (1:1000 in PBS-TSM, Sigma, Lisses d'Abeau Chesnes, France) or 100 µL of mouse anti-bovine/ovine IgA (1:250 in PBS-TSM, Argene, Varilhes, France) were added to each well and incubated for 30 min at 37 °C before washing a further three times in PBS-T. Then for IgA determination, 100 µL of a HRP labelled polyclonal anti-mouse IgG was added to each well (1:750 in PBS-TSM, Argene) and incubated for 1 h at 37 °C. Finally 100 µL of the HRP substrate (o-phenylenediamine 0.4 mg/mL) was added to each well and incubated for 30 min at 37 °C for the IgA and IgG method. Optical densities were read with a Dynatech plate reader (LabSystem, Winooski, Vermont, USA) at 450 nm.

2.8. Statistical analysis

The cellular counts were processed as follows: the results of examinations (5 optical fields / anatomical site / animal) were pooled and the means and standard deviations within the infected and the control groups were calculated. These data were compared by the Student test using a test correction since the variances between the two groups were different.

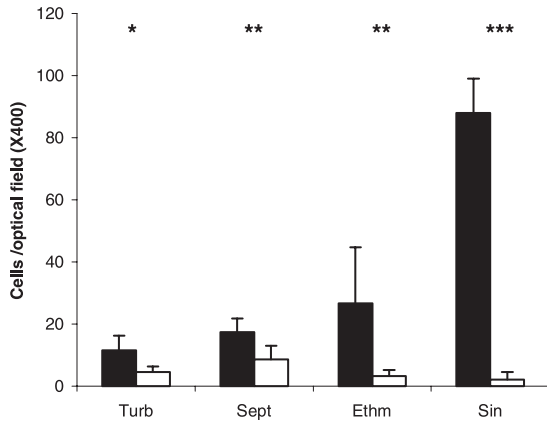


Figure 1. Ki-67 epitope expression in turbinates, septum, ethmoid and sinus mucosae of the control (white bars) and infected lambs (black bars).

3. RESULTS

3.1. Larval burden

No larvae were recovered from the control group. The percentages of larval establishment varied from 6.5% to 17% (mean: 11.2% and standard deviation: 3.8%) in the infected group. Larval burdens were not significantly different between the infected animals ($m = 12.3 \pm 2.1$) (data not shown). Moreover there were no significant differences in the proportions of different instar larvae between the infected animals with the presence of L1 and developing stages (L2 and L3) in all infected animals.

3.2. Mucosa alterations in infected animals

General post mortem examination did not reveal any pathology other than oestrosis. All six infected lambs presented a moderate mucus discharge. The macroscopic observation of the nasal and sinus mucosae revealed strong inflammatory changes and the sinus epithelium was extremely thickened compared to the control animals. In the epithelium of infected animals, Ki67 stained cells were 2.5 ($p < 0.05$), 2.0 ($p < 0.01$), 8.1 ($p < 0.01$) and

40.0 ($p < 0.001$) times more numerous than in the control lambs on the turbinate, septal, ethmoid and sinus surfaces respectively (Fig. 1). The epithelium of the sinus mucosa showed hyperplasia and metaplasia as well as reductions in goblets cells and cilia and an eosinophilic exocytosis. Multifocal irregularities and oedema were seen in the lamina propria and the chorion, respectively (Tab. I).

3.3. Local recruitment of leucocytes

Intra-epithelial and perivascular staining of CD3⁺ cells did not show any differences between infected and control animals (Data not shown). In contrast, significant differences ($p < 0.001$) were observed between the chorion of two groups especially in the ethmoid and sinus compartments (Fig. 2A). CD20⁺ cell numbers were increased in the infected group ($p < 0.001$) (Fig. 2B). CD3⁺ and CD20⁺ cell numbers increased gradually from the turbinates to the sinus. Plasma cells were localised near secretory glands in the sub-epithelial region. Their number was moderate in the septal and turbinate mucosa but the ethmoid and sinus mucosae showed a huge recruitment of plasma cells (Fig. 2D). CD68⁺ cells were significantly more numerous in all locations of the infected animals, except in the turbinate region

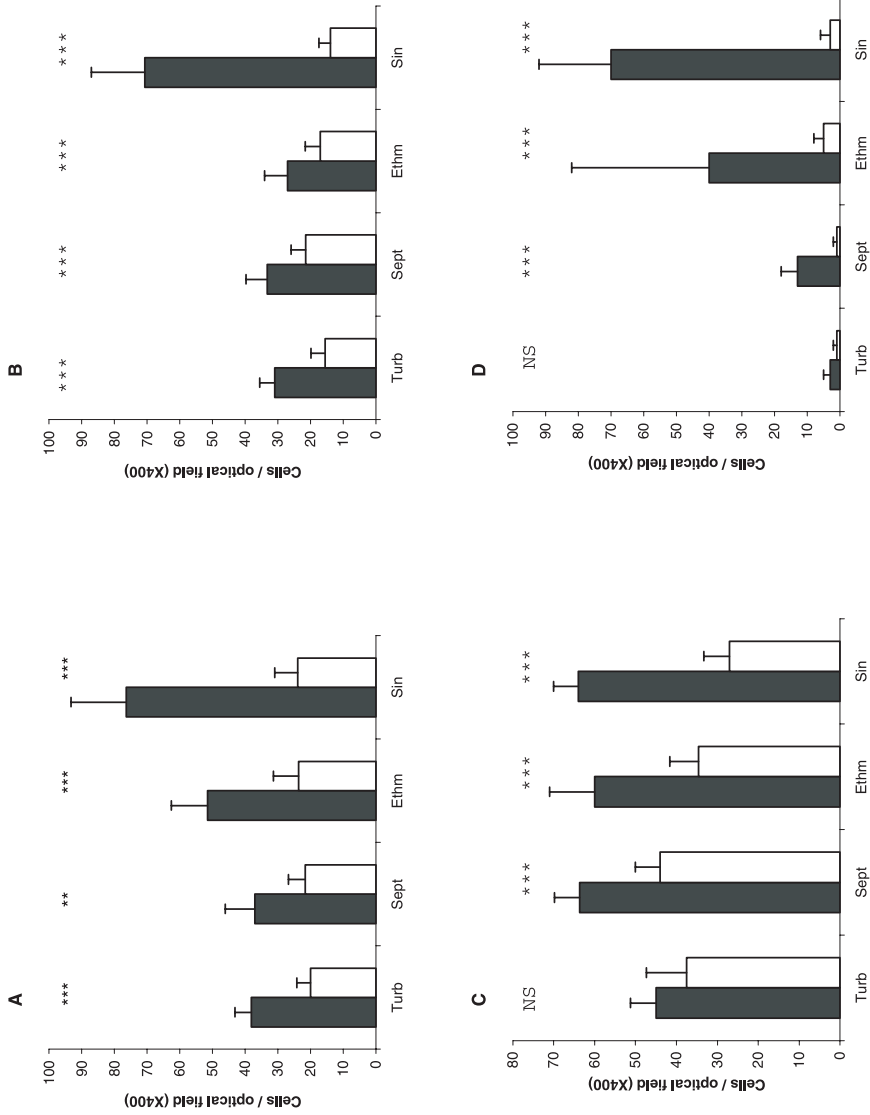


Figure 2. CD3+ cells (A), CD20+ cells (B), CD68+ cells (C), Plasma cells (D) in turbinates, septum, ethmoid and sinus mucosae of the control (white bars) and infected lambs (black bars).

where no difference between the infected and control lambs was observed (Fig. 2C). The presence of *O. ovis* larvae also induced a high recruitment of granulocytes in all locations: eosinophils, mast cells and globule leucocytes were more numerous in infected than in control animals. Moreover, as for leucocytes, their number was dramatically increased in the ethmoid and sinus compartments (Figs. 3A, 3B and 3C).

3.4. Local humoral response

Infected lambs showed *Oestrus ovis* specific IgG (Fig. 4A) and IgA (Fig. 4B) antibodies in their mucus when ELISA plates were coated with excretory secretory products or salivary gland contents. No differences in optical densities were observed between the infected and control animals when the ELISA plates were coated with digestive tube contents. Coating with SGc resulted in higher OD values than with ESP as the antigen (Figs. 4A and 4B).

4. DISCUSSION

The larval establishment rate (11.2%) resulting from three infections with a total of 110 L1 per lamb was comparable to that obtained previously [22]. However a better establishment (39%) was observed when repeated infections were made with L1 directly harvested *ex utero* of gravid *O. ovis* females [5]. Possibly, the L1 collected from fly abdomens are more viable than those taken from naturally infected sheep. Another explanation could be that the L1 collected from sheep might have already been exposed to the complement or immunoglobulin and therefore might be more quickly targeted when re-implanted in a naive sheep. Larval development (assessed by the presence of L2 and L3) occurred in all infected animals.

In *O. ovis* infected lambs, the hyperplasia and metaplasia of the sinus epithelium

suggested the existence of a highly regenerative process. This was corroborated by the expression of the Ki67 cellular proliferation marker, which was 40 times more abundant in the sinus epithelium of infected compared to control lambs, and by the ultrastructural changes observed, namely the epithelial cells were dissociated, rounded and showed signs of degeneration [8].

The expression of the transmembrane protein CD20 is restricted to pre-B lymphocytes in bone marrow and mature B cells; plasma cells do not express CD20 [2, 12] which is why these cells were identified on a morphological basis in histochemistry. CD68 is a glycoprotein mostly localised in lysosomes and specific for macrophages and cells of the mononuclear phagocytic system [7, 16]. Infection of nasal and sinus cavities by *O. ovis* larvae led to a strong mucosal cellular immune response and significantly more leucocytes than control lambs. The presence of large numbers of macrophages suggested active antigen presentation to recruited T lymphocytes. CD3⁺, CD20⁺ and CD68⁺ cell numbers increased gradually from the turbinates to the sinus suggesting that T and B lymphocytes and phagocytic mononuclear cells were essentially recruited to where larval moults take place i.e. where L2 and L3 larvae are found. Similar observations could be made with eosinophils, mast cells and globule leucocytes. Moreover, a significant eosinophilic exocytosis was shown in the sinus cavities, possibly suggesting that these cells were passing through the epithelium to reach the larvae. Similar local cellular responses have been observed in the skin of sheep infected with *Lucilia cuprina* larvae [1] or in the gut mucosae of sheep infected with gastrointestinal nematodes [13, 19]. The numerous plasma cells found in the *O. ovis* infected animals were likely to be responsible for the local IgG and IgA responses, even though specific staining to characterise the immunoglobulin isotypes was not

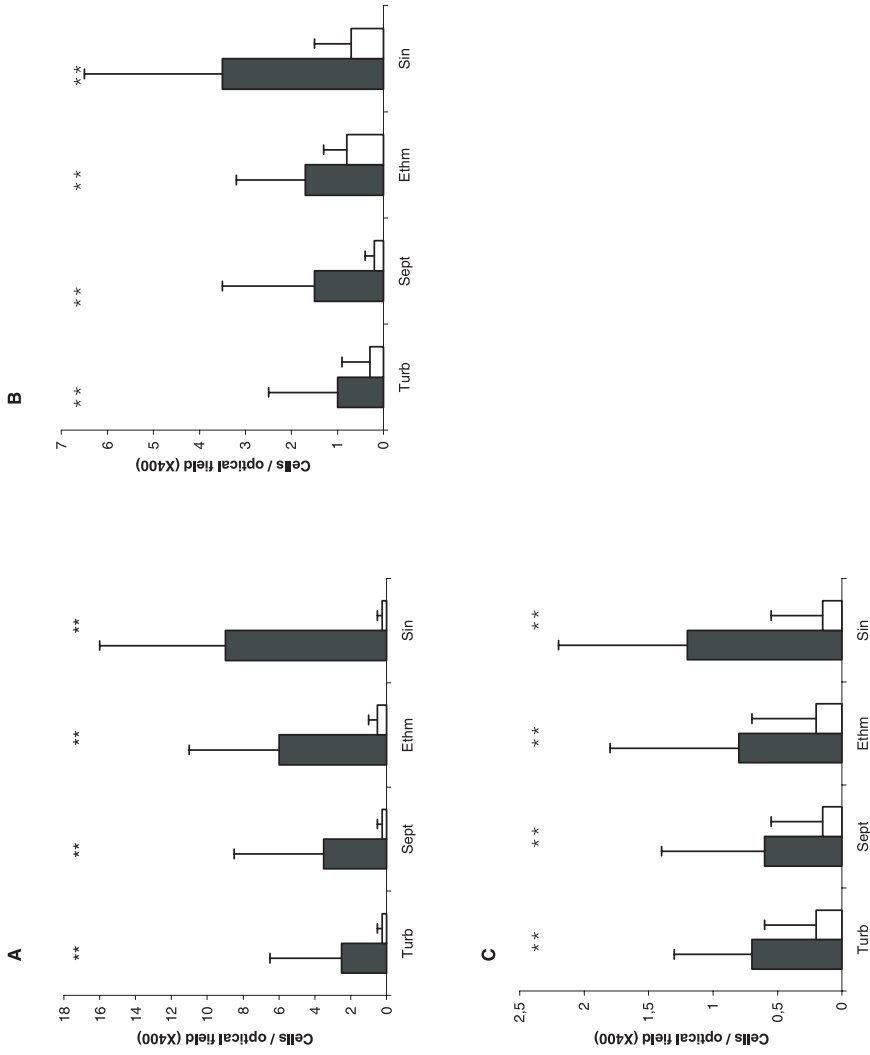


Figure 3. Eosinophils (A), Mast cells (B), Globule leucocytes (C) in turbinates, septum, ethmoid and sinus mucosae of the control (white bars) and infected lambs (black bars).

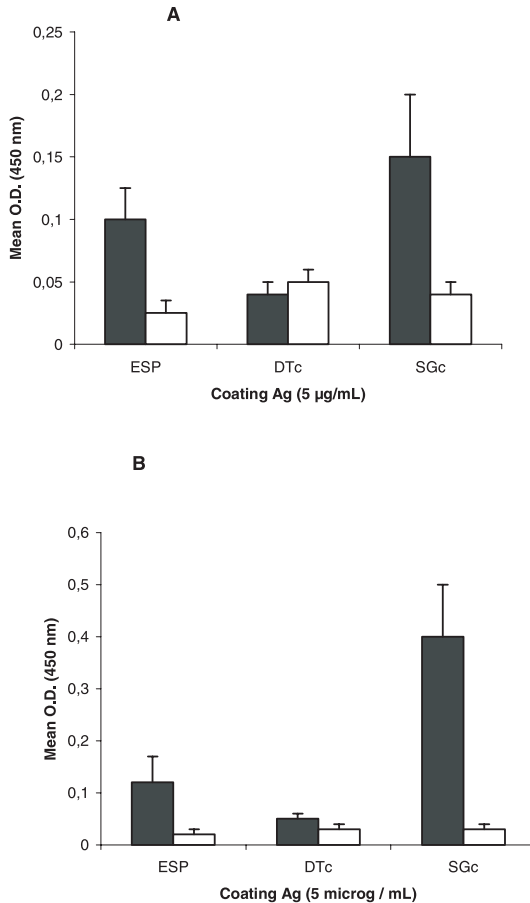


Figure 4. Mucus IgG (A) and IgA (B) antibodies (at the necropsy date). Control lambs: white bars; infected lambs: black bars. ESP: excretory / secretory products, DTc: digestive tube content of L3 larvae, SGc: salivary gland content of L3 larvae.

carried out. Larval salivary gland antigens are strongly recognised by local IgG and IgA antibodies and by circulating IgG antibodies [9, 21]. In contrast, mucus and serum immunoglobulins reacted weakly with *O. ovis* gut soluble proteins (this study and [21]). Recently we found that the *O. ovis* larval gut secretes serine proteases [20] but it is known that the proteases of the pathogens are frequently weakly immunogenic because of their structural homology with the host ones [10]. Local IgG and IgA humoral responses have been observed in the abomasal mucosa of sheep parasitised by *Haemonchus contortus* or *Teladorsagia circumcincta* [6, 17]. What is

the role of such anti-parasitic cellular and humoral local immune responses? Local antibodies, especially IgA, have been clearly associated with worm stunting and reduced fecundity with *Teladorsagia circumcincta* infections in lambs [18]. In *O. ovis* infections, local IgG and IgA recognise mainly salivary gland antigens whose functions are not known. Conversely, serine-proteases from the digestive tract which are essential for the nutrition and the growth of larvae [20] are poorly recognised by these antibodies. This could explain why the immunisation of lambs with excretory-secretory products of *Oestrus ovis* larvae leads only to slight

larval growth inhibition [5]. Eosinophils can adhere to, and immobilise the invasive L3 larval stage of *H. contortus* in vitro cultures in the presence of specific anti-parasitic antibodies suggesting that helminth parasites can be compromised through the co-operative action of antibodies and eosinophils. Since exocytosis of eosinophils and the presence of specific IgG and IgA antibodies in the sheep upper airways have been demonstrated in our study, a similar mechanism could be proposed for the regulation of *O. ovis* larvae.

REFERENCES

- [1] Bowles V.M., Grey S.T., Brandon M.R., Cellular immune responses in the skin of infected sheep with larvae of *Lucilia cuprina*, the sheep blowfly, *Vet. Parasitol.* 44 (1992) 151-162.
- [2] Cartun R., Coles F., Pastuszak W., Utilisation of monoclonal antibody L26 in the identification and confirmation of B-cell lymphomas. A sensitive and specific marker applicable to formalin and B5-fixed paraffin embedded tissues, *Am. J. Pathol.* 129 (1987) 415-421.
- [3] Cepeda-Palacios R., Avila A., Ramirez-Orduna R., Dorchies P., Estimation of the growth patterns of *Oestrus ovis* L. larvae hosted by goats in Baja California Sur, Mexico, *Vet. Parasitol.* 86 (1999) 119-126.
- [4] Dorchies P., Duranton C., Jacquet P., Pathophysiology of *Oestrus ovis* infection in sheep and goats: a review, *Vet. Rec.* 142 (1998) 487-489.
- [5] Frugere S., Cota-Leon A., Prévot F., Cepeda-Palacios R., Tabouret G., Bergeaud J., Duranton C., Dorchies P., Jacquet P., Immunisation of lambs with excretory secretory products of *Oestrus ovis* third instar larvae and subsequent experimental challenge, *Vet. Res.* 31 (2000) 527-535.
- [6] Gill H.S., Husband A.J., Watson D.L., Localization of immunoglobulin-containing cells in the abomasum of sheep following infection with *Haemonchus contortus*, *Vet. Immunol. Immunopathol.* 31 (1992) 179-187.
- [7] Holness C.L., Simmons D.L., Molecular cloning of CD68, a human macrophage marker related to lysosomal glycoproteins, *Blood* 81 (1993) 1607-1613.
- [8] Hoste H., Tabouret G., Jacquet P., Moureu A.M., Bergeaud J.P., Duranton C., Prévot F., Yacob H.T., Dorchies P., Ultrastructural changes following a single infection of the nasal mucosae with *Oestrus ovis* in sheep, 18th International Conference of the World Association for the Advancement of Veterinary Parasitology, Stresa, Italia, 26-30 August 2001.
- [9] Innocenti L., Masetti M., Macchioni G., Giorgi F., Larval salivary gland proteins of the sheep nasal bot fly, (*Oestrus ovis* L.), are major immunogens in infested sheep, *Vet. Parasitol.* 60 (1995) 273-282.
- [10] Kumar S., Selective modification and immune evasion: a hypothesis, *Immunol. Cell Biol.* 71 (1993) 141-143.
- [11] Marchenko V.A., Marchenko V.P., Survival of the larvae of the sheep botfly *Oestrus ovis* L. depending on the function of the immune system of the host's body, *Parazitologiya* 23 (1989) 129-133.
- [12] Mason D.Y., Commans-Bitter W.M., Cordell J.L., Verhoeven M.A., Van Dongen J.J., Antibody L26 recognizes an intracellular epitope on the B-cell-associated CD20 antigen, *Am. J. Pathol.* 136 (1990) 1215-1222.
- [13] Miller H.R., Mucosal mast cells and the allergic response against nematode parasites, *Vet. Immunol. Immunopathol.* 54 (1996) 331-336.
- [14] Nguyen V.K., N., Bourges N., Concordet D., Dorchies P., Mast cells and eosinophils counts in the respiratory mucosae of sheep naturally infected with *Oestrus ovis* (Linné 1761), *Parasite* 6 (1996) 217-221 (in French).
- [15] Nguyen V.K., Jacquet P., Duranton C., Bergeaud J.P., Prévot F., Dorchies P., Cellular reactions of nasal and sinus mucosae of goats and sheep naturally infected with *Oestrus ovis* Linné 1761 (Diptera: Oestridae), *Parasite* 2 (1999) 141-149 (in French).
- [16] Pulford K.A., Rigney E.M., Micklem K.J., Jones M., Stross S.P., Gratter K.C., Mason D.Y., KP1: a new monoclonal antibody that detects a monocyte/macrophage associated antigen in routinely processed tissue sections, *J. Clin. Pathol.* 42 (1989) 414-421.
- [17] Sinski K., Bairden K., Duncan J.L., Eisler M.C., Holmes P.H., McKellar Q.A., Murray M., Stear M.J., Local and plasma antibody responses to the parasitic larval stages of the abomasal nematode *Ostertagia circumcincta*, *Vet. Parasitol.* 59 (1995) 107-118.
- [18] Stear M.J., Strain S., Bishop S.C., How lambs control infection with *Ostertagia circumcincta*, *Vet. Immunol. Immunopathol.* 72 (1999) 213-218.

- [19] Stevenson L.M., Huntley J.F., Smith W.D., Jones D.G., Local eosinophils-and mast cell-related responses in abomasal nematode infections of lambs, *Immunol. Med. Microbiol.* 8 (1994) 167-174.
- [20] Tabouret G., Bret-Bennis L., Lacroux C., Andreoletti O., Hoste H., Bergeaud J.P., Prévot F., Duranton C., Dorchies P., Jacquet P., *Oestrus ovis* (Diptera: Oestridae): excretory secretory serine proteases and associated mucosal immune response, 18th International Conference of the World Association for the Advancement of Veterinary Parasitology, Stresa, Italia, 26–30 August 2001.
- [21] Tabouret G., Prévot F., Bergeaud J.P., Dorchies P., Jacquet P., *Oestrus ovis* (Diptera: Oestridae): sheep humoral immune response to purified excreted/secreted salivary gland 28 kDa antigen complex from second to third instar larvae, *Vet. Parasitol.* 101 (2001) 53-66.
- [22] Yilma J., Dorchies P., Essais d'infestation expérimentales de l'agneau par des larves I d'*Oestrus ovis*, *Bull. Soc. Franç. Parasitol.* 11 (1993) 43-47.
- [23] Zumpt F., *Myiasis in man and animals of the old world*, Butterworths, London, 1965, 267 p.