

Quantitative modification of the testicular structure in pigs fed with anabolic doses of clenbuterol

Alfonso BLANCO^a, Emilio ARTACHO-PÉRULA^b, Rafaela FLORES-ACUÑA^a,
Eduardo AGÜERA^a, Jose G. MONTERDE^{a*}

^a Departamento de Anatomía y Anatomía Patológica Comparadas, Universidad de Córdoba,
14071 Córdoba, Spain

^b Departamento de Ciencias Médicas, Universidad de Castilla la Mancha, 02071 Albacete, Spain

(Received 10 April 2001; accepted 13 August 2001)

Abstract – Morphological and structural data of the testes of thirty male pigs were recorded in order to evaluate the effects of an anabolic clenbuterol treatment. Pigs aged 6 months were randomly allocated to one of three experimental groups. In two treated groups, the animals were fed with anabolic doses of clenbuterol (1 ppm); in the CLB group ($n = 10$) clenbuterol was given until they were slaughtered (treatment period = 3 months) whereas in the CLBW group ($n = 10$) the clenbuterol was withdrawn two weeks before slaughter (treatment period = 2.5 months); clenbuterol was not given to the pigs of the control group ($n = 10$). Stereological estimations of the tissular volume fraction and tubular volume density were applied to quantify the structural constituents of the testes. The results showed an increased volume fraction of the testicular interstitium especially in the Leydig cell population, as a result of the clenbuterol treatment. The increase in the nuclear volume fraction of the Leydig cells was the more persistent change in the variations recorded in both treated groups with respect to the control. A regression of the seminal epithelium was also recorded in the treated animals. The rest of the structural parameters were closer to the normal figures in the CLBW group, suggesting a recovery of the testicular structure when clenbuterol was withdrawn.

clenbuterol / pig / testes / testicular structure / Leydig cell

Résumé – **Modification quantitative de la structure testiculaire chez des porcs nourris avec des doses anabolisantes de clenbutérol.** Les données morphologiques et structurales des testicules de trente porcs ont été recueillies afin d'évaluer les effets d'un traitement anabolisant à base de clenbutérol. Les porcs ont été distribués de façon aléatoire dans chacun des trois groupes expérimentaux : dans deux des groupes traités les animaux ont été nourris avec des doses anabolisantes de clenbutérol (1 ppm); dans le groupe CLB ($n = 10$) le clenbutérol a été administré aux animaux jusqu'à l'abattage (période de traitement = 3 mois) alors que dans le groupe CLBW ($n = 10$) le clenbutérol a été retiré de

* Correspondence and reprints

Tel.: (34) 957218675; fax: (34) 957218847; e-mail: jg.monterde@uco.es

l'alimentation deux semaines avant l'abattage (période de traitement = 2,5 mois); le clenbutérol n'a pas été administré aux porcs du groupe témoin ($n = 10$). Les estimations stéréologiques de la fraction du volume tissulaire et de la densité du volume tubulaire ont été utilisées pour quantifier les constituants structuraux des testicules. Un accroissement de la fraction du volume de l'interstitium testiculaire et surtout de la population des cellules de Leydig (fraction de volume occupée par les noyaux) a été la modification la plus persistante des variations recueillies dans les deux groupes traités par rapport au groupe témoin. Une régression de l'épithélium séminal a également été notée chez les animaux traités. Le reste des paramètres structuraux étaient plus proches des schémas normaux dans le groupe CLBW suggérant un retour à la normale des structures testiculaires lorsque le clenbutérol est retiré.

clenbutérol / porc / testicule / structure testiculaire / cellule de Leydig

1. INTRODUCTION

Clenbuterol is a β_2 -adrenergic agonist with veterinary therapeutic recommendations for bronchodilatation in horses and calves and for tocolysis in cows. Clenbuterol also has known applications as a growth promoter as a result of its ability to diminish carcass adipose tissue accretion, thereby satisfying the consumer demand for lean meat. Nevertheless, no β -agonists are permitted in the European Community for growth promoting purposes in farm animals because of their potential hazard to human and animal health [12].

Several workers have widely reported the many side effects from clenbuterol treatments. Biolatti et al. [2] have described severe alterations in the ovaries of female pigs treated with clenbuterol including macroscopic and histopathologic lesions as well as ovarian hormonal disorders. Groot et al. [8] observed impaired development of the testes in veal calves treated with clenbuterol.

Recently several lines of evidence have supported the role of peripheral catecholamines in the control of the male gonadal function. It has been demonstrated that both β_1 and β_2 -adrenergic receptors have a high expression in the testes [14]. The β_1 -adrenergic receptors have been found above all in Sertoli cells [6, 11] whereas the β_2 -adrenergic receptors have been correlated with the essential role possibly played

by catecholamines in testosterone productions from the Leydig cells [5, 13].

In spite of this, little is known about the possible effects of the β_2 -agonist clenbuterol on testicular structure. Thus, the purpose of this article was to histomorphometrically evaluate the consequences of the β_2 -agonist clenbuterol, administered to pigs at anabolic doses, on the testicular structure regarding the possible reversibility of the clenbuterol changes induced.

2. MATERIALS AND METHODS

2.1. Animals and experimental design

Thirty Landrace \times Large white, six month old male pigs were randomly allocated in one of three experimental groups. The animals, in a good state of health and with no previous history of disease, were fed, on an ad libitum basis, a diet of corn, soybean meal and premix calculated to contain 14% protein (they were fed approximately 2.3 kg/d). In the treated groups, 1 ppm of clenbuterol hydrochloride (Sigma, St. Louis, MO, USA) was added to the diet. In the CLB group ($n = 10$) clenbuterol was given until the end of the experimental period (for three months) whereas in the CLBW group ($n = 10$) clenbuterol was withdrawn two weeks before slaughter, so that clenbuterol was administered for 2.5 months. In the control group ($n = 10$) no clenbuterol was given. At

nine months of age, they were slaughtered under surveillance in an authorized abattoir, although the carcasses of these animals were not destined for human consumption.

The testes were removed from the carcasses by cutting the spermatic cord at the level of the tail of the epididymis and one testis from each animal was randomly chosen for this study. The selected organs were weighed and cut perpendicularly to the major axis into a series of slabs of ~ 15 mm thickness beginning at a random position with respect to the testis (6–8 slabs were obtained). At this stage the volume of the testis was determined by the Cavalieri principle as described in the stereological methods. For histological procedures, a simple sampling scheme for vertical sections was applied and 6–9 blocks per specimen were chosen applying the fractionator principle [9]. Each selected block was then histologically processed, fixed in 10% formaldehyde, dehydrated in a graded series of ethanol, immersed in xylol and embedded in paraffin wax. The first section (4 µm thick) of each block was stained with haematoxylin and eosin and used for the stereological and structural study.

2.2. Stereology

2.2.1. Volume estimation

The testicular volume was estimated based on the principle of Cavalieri [4] from the cross-sectional areas of the slabs of each testis. The area was estimated by superimposing a transparent test point system on the slabs and counting the points that fell on the testicular sectional area. The test system used was previously chosen to ensure that 80–100 points would hit the entire set of sectional profiles. The calculation was :

$$\text{est}V = \Sigma P(\text{tes}) \times a \times t,$$

where $\text{est}V$ is the calculated volume, $\Sigma P(\text{tes})$ is the total number of points which hit the

testicular tissue, a is the area equivalent of one test point (in our study, $a = 2 \text{ cm}^2$) and t is the slice separation (in our study $t = 1.5 \text{ cm}$).

2.2.2. Tissue volume fraction

The study included the quantification of the volume fraction of the interstitial and epithelial tissues of the organ using an integral test system of regularly spaced points, which was superimposed on low magnified testicular images (Fig. 1, C) on a color monitor, by using Visilog 5[®] software. A subset of approximately 90 systematically selected fields of view per organ was counted. Thus, the volume fractions were obtained from:

$$\text{est}V_v(\text{tiss/test}) = \frac{\Sigma P(\text{tiss})}{\Sigma P(\text{test})},$$

where $\text{est}V_v(\text{tiss/test})$ is the tissue volume fraction, and $\Sigma P(\text{tiss})$ and $\Sigma P(\text{test})$ are the total number of points which hit the tissue and the testis, respectively.

The study also measured the nuclear volume fraction of the Leydig cells by using the same integral test system of regularly spaced points on high magnifications of the interstitial tissue images.

2.2.3. Length density of testicular tubules

The length of the linear structures may be referred to a volume counting the profiles intersected within a delimited test area (Fig. 1, A) by the formula :

$$\text{est}L_v(\text{tub/test}) = 2 \times \Sigma Q / \Sigma A,$$

where $\text{est}L_v(\text{tub/test})$ is the total length of seminiferous tubules per unit of testicular volume; ΣQ and ΣA are the total of the profiles of seminal tubules and the total of the delimited test area, respectively.

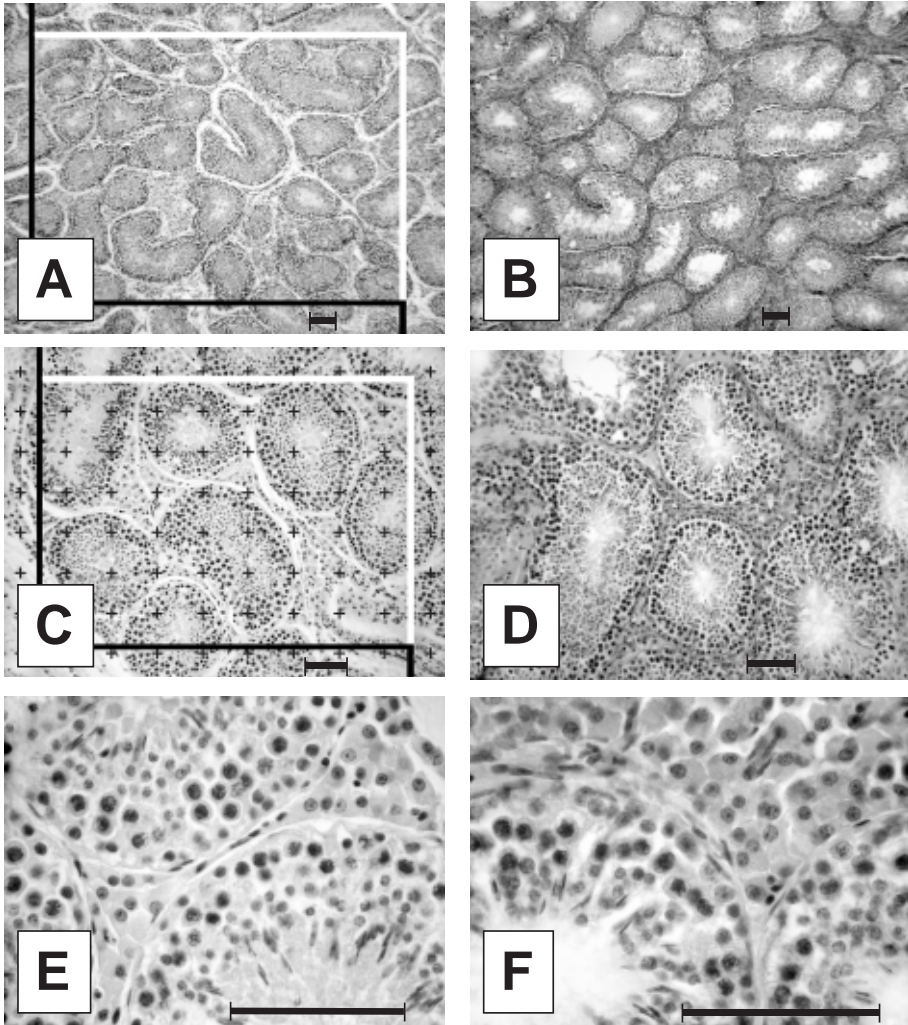


Figure 1. Photomicrographs of sections of the control testes (A, C and E) and clenbuterol-treated (B, D and F) pigs. Note the increase in the interstitium and the decrease in the seminal epithelium in the clenbuterol-treated images as compared to the control. The test system superimposed in (A) and (C) was used in the estimation of the tubular length density and volume fraction, respectively. Scale bar = 100 μ m.

2.3. Statistical analysis

Statistical results are expressed as the mean \pm standard deviation. For the null hypothesis that the values were a random sample from a normal distribution the Kolmogorov-Smirnov test was applied. The statistical

significance of differences between groups was determined in the parameter analysed by a one-way analysis of variance (ANOVA). When a significant difference between groups was observed ($P < 0.05$) a post-hoc Scheffe test was carried out in order to perform pairwise comparisons between group means.

3. RESULTS

The testes of both clenbuterol groups (CLB and CLBW) showed a significant decrease in weight and volume compared with the control group (Tab. I). There was also a greater fibrous consistence when testes from the clenbuterol groups were cut into slabs compared to those from the control group. No other additional macroscopic differences were observed.

Regarding the tissue constituents, the volume fraction of the interstitium was clearly increased in the clenbuterol groups (CLB and CLBW) with respect to the control (Tab. I and Fig. 2). This increase was

quantified by the interstitial tissue volume fraction whose figures were higher in the clenbuterol-administered groups with respect to the control. More outstanding were the data concerning the interstitial (Leydig) cells, which were clearly distributed as broad clusters throughout the connective tissue between the seminiferous tubules. Their acidophilic cytoplasm with a foamy appearance were especially evident in the testes of the clenbuterol treated groups (Fig. 1). The quantification of the volume fraction of the interstitium occupied by the nuclei of the Leydig cells showed a significant increase in both clenbuterol treated groups as compared to the control (Tab. I),

Table I. Quantitative data for control and treated groups.

Item	Control Mean ± sd	CLBW ^a Mean ± sd	CLB ^a Mean ± sd	Statistical significance (ANOVA) ^c		
				Control Vs CLBW	Control Vs CLB	CLB Vs CLBW
Live weight (kg)	129.65 ± 5.96	126.5 ± 8.55	125 ± 7.66	ns	ns	ns
Testicular weight (g)	347.9 ± 56.77	284.1 ± 58.49	286.0 ± 37.69	*	*	ns
Testicular/live weight (%)	0.27 ± 0.05	0.22 ± 0.4	0.22 ± 0.16	*	*	ns
Testicular volume (cm ³)	295.94 ± 55.17	240.35 ± 51.30	240.42 ± 31.77	*	*	ns
<i>V_v</i> (Inst/tes) (%) ^b	21.22 ± 6.85	25.78 ± 4.22	30.33 ± 5.80	ns	**	ns
<i>V_v</i> (Leydig/Inst) (%) ^b	2.52 ± 0.54	5.98 ± 1.25	6.01 ± 1.18	***	***	ns
<i>V_v</i> (Epith/test) (%) ^b	69.87 ± 6.24	66.14 ± 4.72	58.40 ± 5.09	ns	***	*
<i>V_v</i> (Lum/test) (%) ^b	8.40 ± 2.58	8.07 ± 2.56	11.26 ± 2.22	ns	*	*
<i>L_v</i> (Tub/test) (cm/cm ³) ^b	29.38 ± 5.99	29.54 ± 6.72	29.18 ± 6.46	ns	ns	ns

^a CLBW: clenbuterol treated group with withdrawal; CLB: clenbuterol treated group without withdrawal.
^b *V_v* (inst/tes), *V_v* (epith/tes) and *V_v* (lum/test), Volume fraction of testes occupied by the interstitium, epithelium and tubular lumen, respectively; *V_v* (Leydig/Inst), Volume fraction of the interstitium occupied by the nuclei of the Leydig cells; *L_v* (Tub/test), Length density of the testicular tubules.
^c ns: not significant; * *P* < 0.05; ** *P* < 0.01; *** *P* < 0.001.

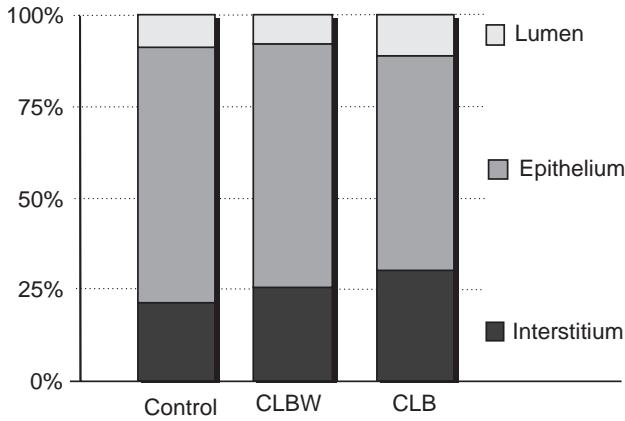


Figure 2. Relative percentage of contribution to the total testicular structure from each volume fraction of its tissular constituents.

and contrary to the interstitium, this figure did not significantly return to normal with clenbuterol withdrawal.

The percentages for the volume fraction of the seminal epithelium decreased, and the tubular lumens increased, in the treated groups with respect to the control (Tab. I and Fig. 2).

No differences between groups were found in the data of the length tubular density.

4. DISCUSSION

In spite of the differences in the methodological procedures, our morphological and structural results for the control group were in the range of the previous data reported for pig testes [10]. The decreases of the testicular weight and volume recorded in the clenbuterol groups with respect to the control are in accordance with the morphological observations of Groot et al. [8] on testes of calves treated with clenbuterol. A decrease in the testicular weight has also been reported in rats treated with clenbuterol [3] but this would be in relation with the clenbuterol-related reduction of the epididymal fat pad observed in these animals, but the testes of the pig were not

characterized for epididymal or testicular adipose deposits. On the contrary adrenergic agents have proved their ability to contract the testicular capsule [7] by providing a pumping action, which could be overstimulated in the clenbuterol-treated animals.

The volume fraction of the interstitial tissue was increased in the testes of the clenbuterol groups with respect to the control. More remarkable and persistent was the increase of the volume fraction of the Leydig cell population exerted by the clenbuterol treatment. This action is in accordance with the previously reported stimulating effect of the β -adrenergic agonists on testosterone production by the Leydig cells [1, 5, 14] and agrees with the increase in the testicular stroma reported by Groot et al. [8] in the testes of calves treated with clenbuterol.

From a functional point of view, the evaluation of the effect of clenbuterol on the seminal epithelium is more difficult. Our quantitative results on the epithelium and lumen of the seminal tubules, together with the lower testicular weight and volume recorded in the treated groups, clearly pointed to a regression of the seminal epithelium as a consequence of the clenbuterol administration. Nevertheless, it would be necessary to carry out a detailed quantification of the cellular

constituents of the seminal epithelium to state more precisely the effects of clenbuterol on spermatogenesis.

The return to the normal figures observed in the CLBW group suggests that the inhibiting effects of clenbuterol on the seminal epithelium are reversible. Nevertheless, it should also be taken into account that the shorter treatment period in the CLBW group might also have reduced the clenbuterol-related alterations in the testicular structure in this group.

In conclusion, an anabolic clenbuterol treatment exerts a clear effect on testicular structure, increasing the interstitial cell population and decreasing the epithelium of the seminiferous tubules. A lesser testicular weight and volume were other morphological changes also recorded as a result of the clenbuterol administration.

ACKNOWLEDGEMENTS

The authors are also grateful to Mrs A.B. Galan Montenegro for skilled technical assistance and Mrs D.C. Badder for providing linguistic help.

REFERENCES

- [1] Anakwe O.O., Moger W.H., β 2-adrenergic stimulation of androgen production by cultured mouse testicular interstitial cells, *Life Sci.* 35 (1984) 2041-2047.
- [2] Biolatti B., Castagnaro M., Bollo E., Appino S., Re G., Genital lesions following long-term administration of clenbuterol in female pigs, *Vet. Pathol.* 31 (1994) 82-92.
- [3] Cartana J., Segues T., Yebras M., Rothwell N.J., Stock M.J., Anabolic effects of clenbuterol after long-term treatment and withdrawal in the rat, *Metabolism* 43 (1994) 1086-1092.
- [4] Cavalieri B., *Geometria Degli Indivisibili*, Unione Tipografico-editrice, Torino, 1966.
- [5] Cooke B.A., Golding M., Dix C.J., Catecholamine stimulation of steroidogenesis in Leydig cells, *Biochem. Soc. Trans.* 10 (1982) 491-493.
- [6] Eikvar L., Bjornerheim R., Attramadal H., Hansson V., β -adrenoceptor mediated responses and subtypes of β -adrenoceptors in cultured rat Sertoli cells, *J. Steroid Biochem. Mol. Biol.* 44 (1993) 85-91.
- [7] Firlit C.F., King L.R., Davis J.R., Comparative responses of the isolated human testicular capsule to autonomic drugs, *J. Urol.* 113 (1975) 500-504.
- [8] Groot M.J., Schilt R., Ossenkoppele J.S., Berende P.L., Haasnoot W., Combinations of growth promoters in veal calves : consequences for screening and confirmation methods, *Zentralbl. Veterinaermed. A* 45 (1998) 425-440.
- [9] Gundersen H., Bendtsen T., Korbo L., Marcussen N., Moller A., Nielsen K., Nyengaard J., Pakkenberg B., Sorensen F., Vesterby A., West M., Some new, simple and efficient stereological methods and their use in pathological research and diagnosis, *Acta Pathol. Microbiol. Immunol. Scand.* 96 (1988) 379-394.
- [10] Harder R.R., Lunstra D.D., Johnson R.K., Growth of testes and testicular morphology after eight generations of selection for increased predicted weight of testes at 150 days of age in boars, *J. Anim. Sci.* 73 (1995) 2186-2192.
- [11] Heindel J.J., Steinberger A., Strada S.J., Identification and characterization of a β 1-adrenergic receptor in the rat Sertoli cell, *Mol. Cell Endocrinol.* 22 (1981) 349-358.
- [12] Kuiper H.A., Noordam M.Y., Dooren-Flipsen M.M., Schilt R., Roos A.H., Illegal use of β -adrenergic agonists : European Community, *J. Anim. Sci.* 76 (1998) 195-207.
- [13] Moger W.H., Murphy P.R., β -adrenergic agonist induced androgen production during primary culture of mouse Leydig cells, *Arch. Androl.* 10 (1983) 135-142.
- [14] Renier G., Gaulin J., Gibb W., Collu R., Ducharme J.R., Effect of catecholamines on porcine Sertoli and Leydig cells in primary culture, *Can. J. Physiol. Pharmacol.* 65 (1987) 2053-2058.